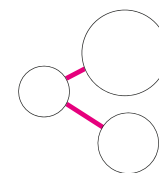


PHARMACEUTICAL-GRADE HYALURONIC ACID GEL

PREDICTABILITY. AESTHETICS.
EASE-OF-USE.



xHyA
Cross-linked Hyaluronic Acid

SEVEN REASONS

TO ADD HYALURONIC ACID IN DENTAL SURGERY

- 1 FASTER TISSUE HEALING**
HA supports angiogenesis^{5,16,19,24} & tissue formation^{8,9,12,13,17,22} over an extended period. Its special formulation remains present throughout the various phases of the healing process due to its slow degradation pattern (several weeks).²²
- 2 GREATER OUTCOME PREDICTABILITY**
HA stabilizes blood clot and attracts growth factors to support and accelerate hard and soft tissue formation.^{15,19-23}
- 3 LOWER RISKS OF INFECTION**
Bacteriostatic action and reduced pathogen penetration.¹⁰
- 4 LESS POST-OP PAIN AND SWELLING FOR PATIENTS**
HA's high molecular weight reduces swelling and discomfort during the healing process.^{18,23}
- 5 BETTER AESTHETICS FOR PATIENT**
Support scar-less wound healing.^{18,23}
- 6 SAVE TIME IN HANDLING BIOMATERIALS**
Apply directly on surgical site (in presence of blood), do not rinse. HA can be combined with Smartgraft to prepare the „sticky bone“ in 3 minutes.
- 7 OPTIMIZATION OF THE PROPERTIES OF OTHER BIOMATERIALS**
When xHyA is combined with graft material hydrophilic properties are enhanced, as well as volume stability²⁴ and remodelling.²⁵ When xHyA is coated on a collagen membrane, its barrier effect is extended.¹⁴

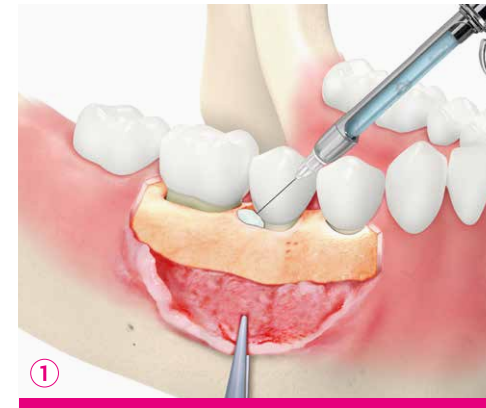CROSS-LINKED HYALURONIC ACID (xHyA)

WHAT IS PHARMACEUTICAL-GRADE CROSS-LINKED HYALURONIC ACID?

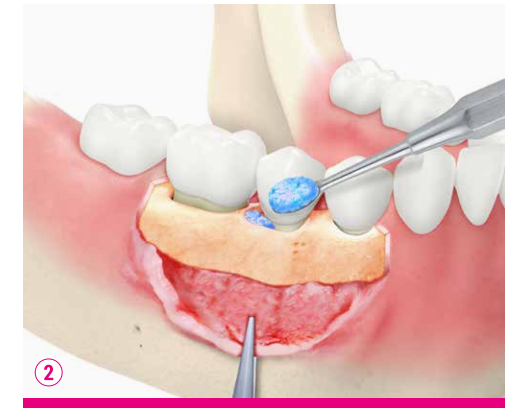Hyaluronic acid, as one of the main components of the extracellular matrix is naturally present in the human body.¹⁻³ Studies have shown that prolonged presence of hyaluronic acid during the healing process promotes healing by regeneration rather than reparation.⁴⁻⁷ Besides accelerating the healing of soft tissue and bone,⁷⁻⁹ the bacteriostatic properties of hyaluronic acid also protect the wound.¹⁰

Cross-linked surgical-grade hyaluronic acid (xHyA) remains present throughout the various phases of the healing process due to its slow degradation pattern (several weeks).¹¹ As shown in different studies, the presence of hyaluronic acid supports and accelerates bone formation.^{8,9,12,13} When mixed with a bone grafting material hyaluronic acid attracts blood into the matrix and protects the wound. Mixing xHyA's gel with the graft material facilitates its handling, on top of providing all xHyA's benefits.

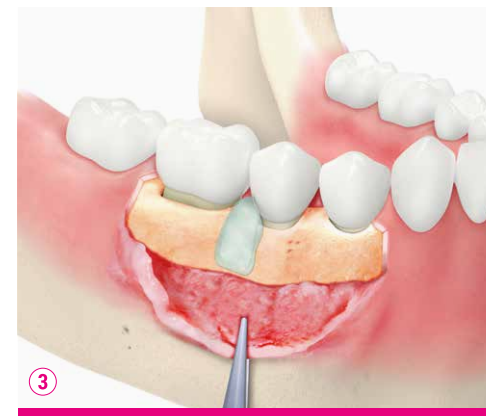HOW IS xHyA GEL USED?



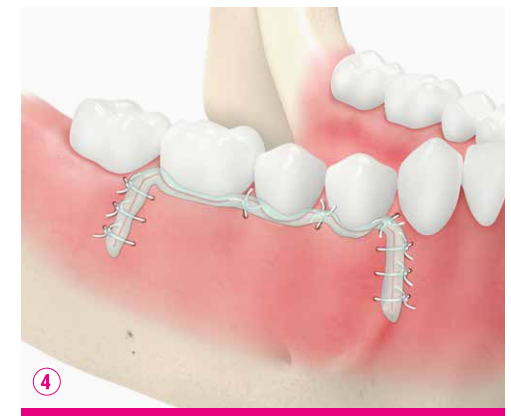Directly into blood-covered surgical site



Mixed with xenograft material, as a 'sticky bone'



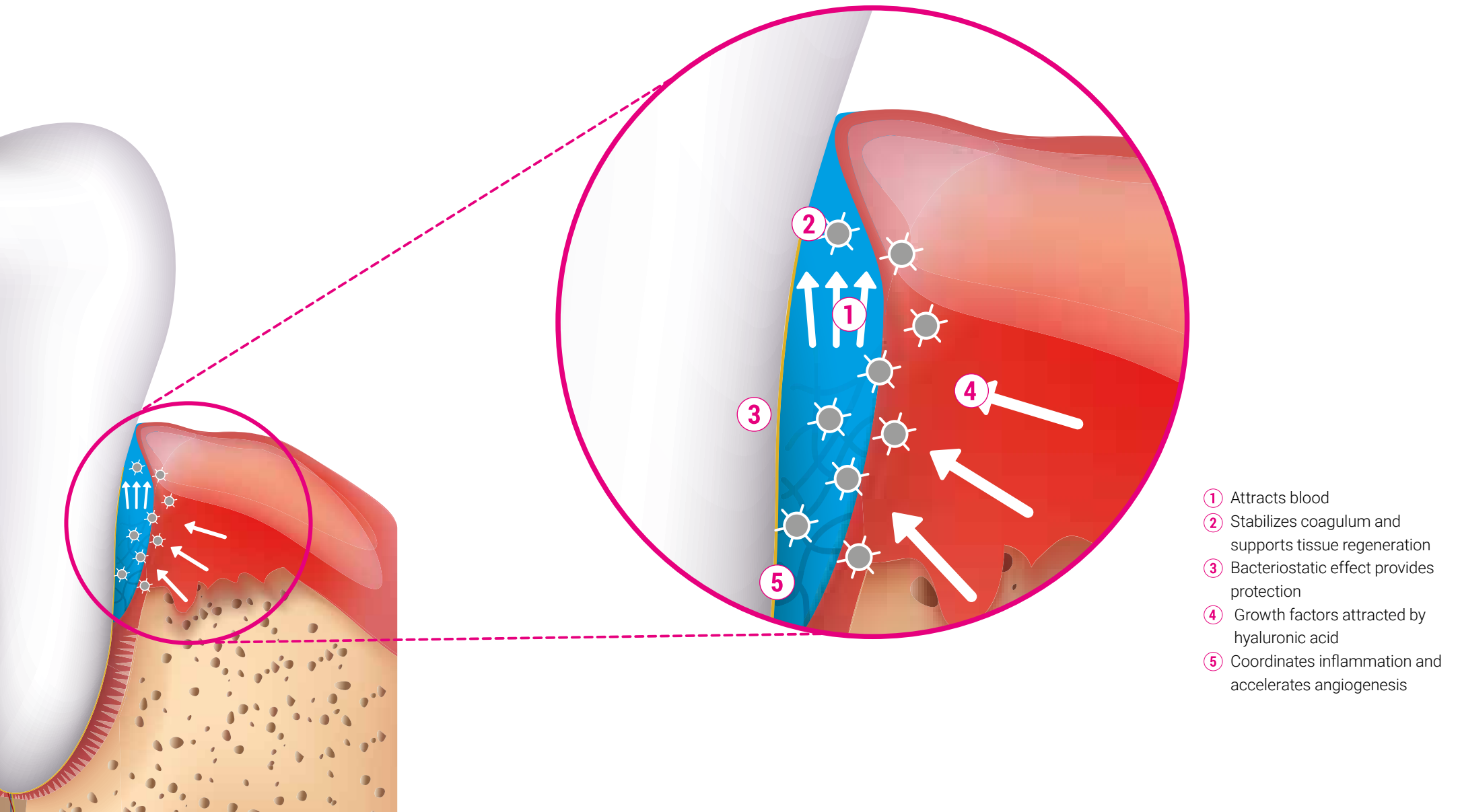
Coating the collagen membrane



Onto sutured site

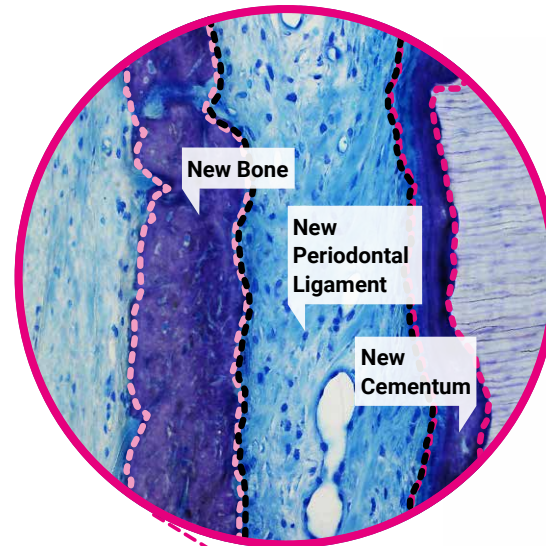
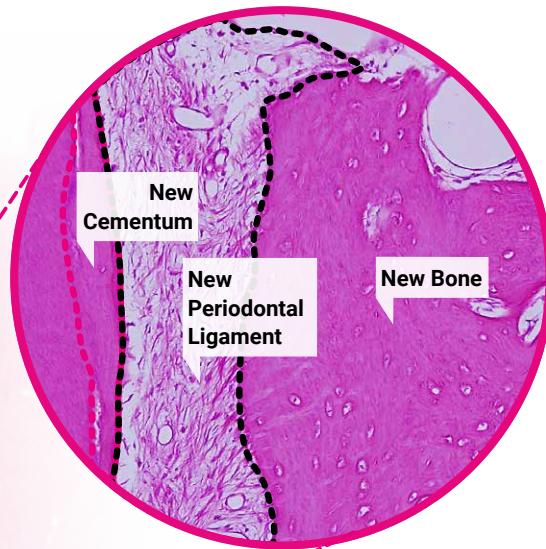
EFFECTS AND MODE OF ACTION

PERIODONTAL REGENERATION: xHyA GEL APPLIED DIRECTLY IN BLOOD-COVERED SITE AND POCKETS

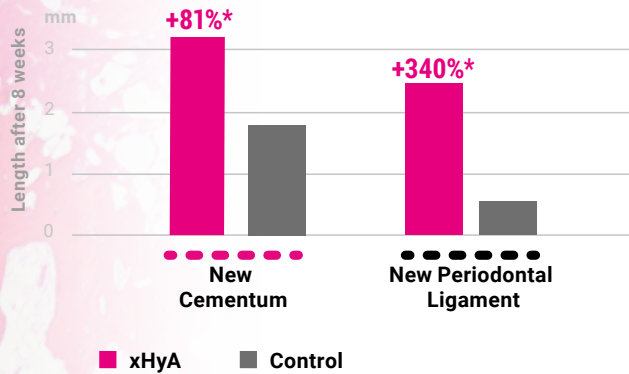


EMPOWERING REGENERATION

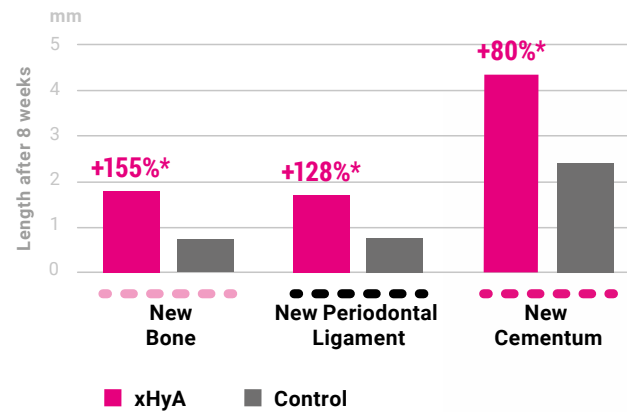
PERIODONTAL SCIENTIFIC EVIDENCE



Regeneration in infrabony defect²²

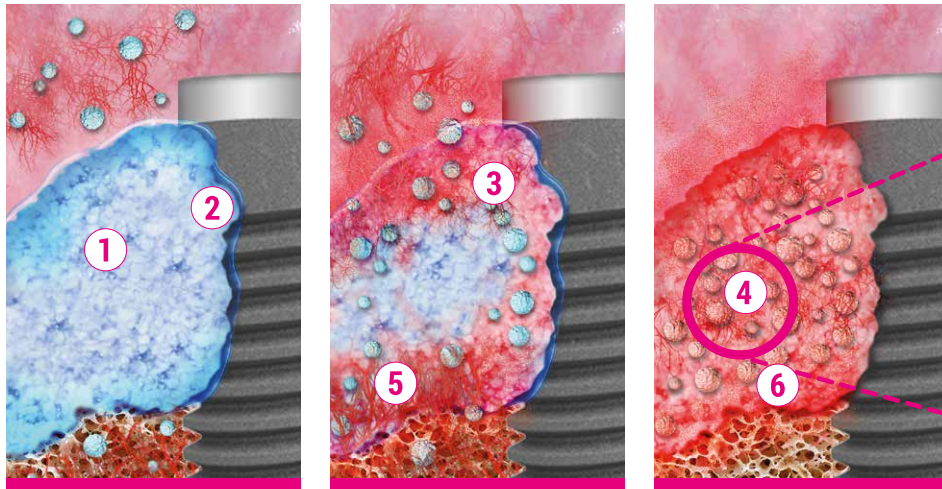


Regeneration in gingival recessions¹⁷

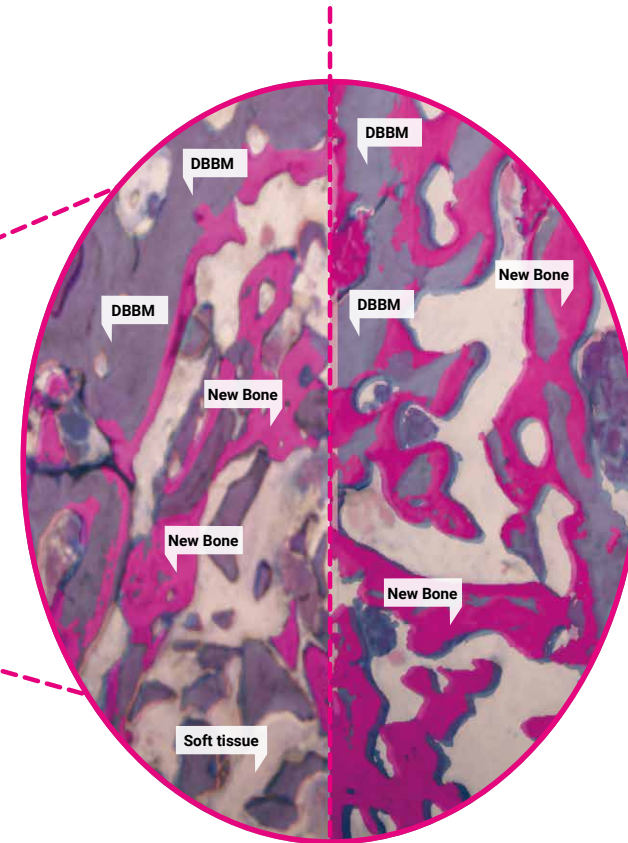


EFFECTS AND MODE OF ACTION

BONE REGENERATION: xHyA GEL IS MIXED WITH THE BONE SUBSTITUTE



- ① Forms stable graft putty with bone substitution material
- ② Attracts blood
- ③ Stabilizes coagulum and supports tissue regeneration
- ④ Growth factors attracted by hyaluronic acid
- ⑤ Bacteriostatic effect provides protection
- ⑥ Coordinates inflammation and accelerates angiogenesis



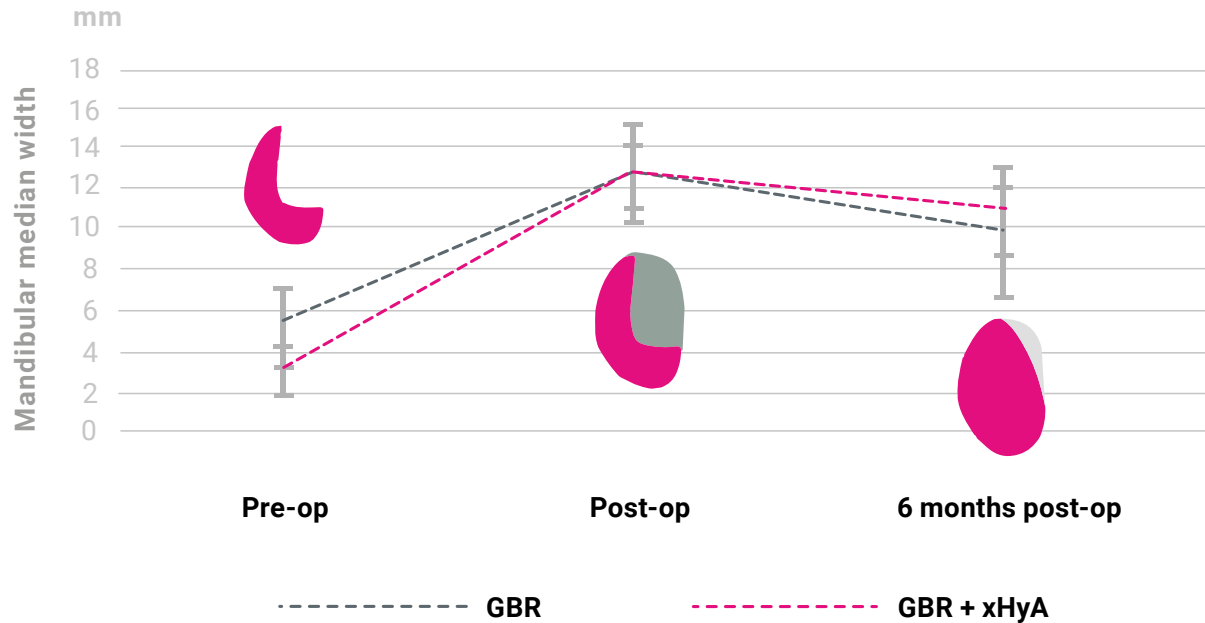
More bone cells, less remnant DBBM
when mixed with xHyA gel.

Histologies after 2 months with DBBM
(left) and DBBM + xHyA (right).²⁵

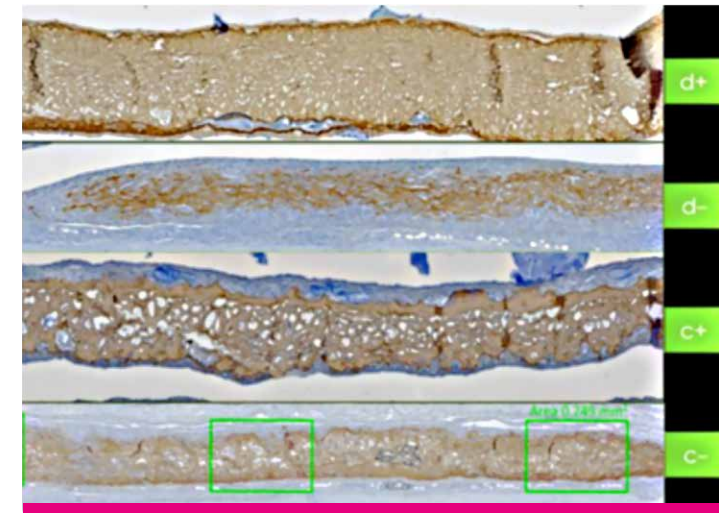
EMPOWERING REGENERATION

SCIENTIFIC EVIDENCE

More bone volume in test group (xHyA + xenograft material)²⁴



Slowed resorption of collagen membrane¹⁴



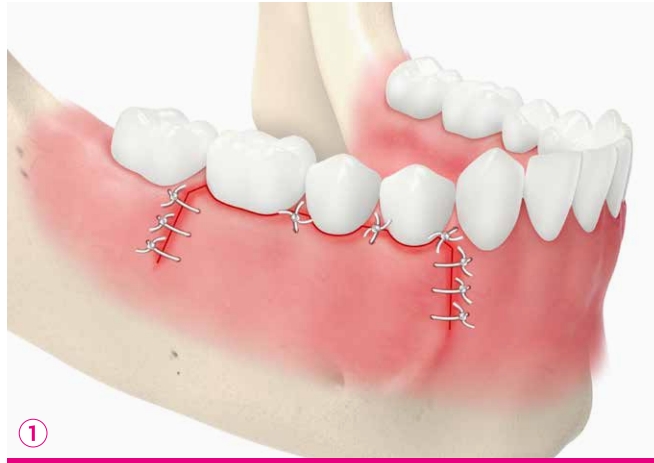Note: Collagen membranes (brown), 14 days after implantation in normoglycemic (C-/C1) or diabetic groups (d-/d+) show less collagen resorption when used with xHyA (d+/c+).^{6,7}

READ THE SCIENTIFIC EVIDENCE

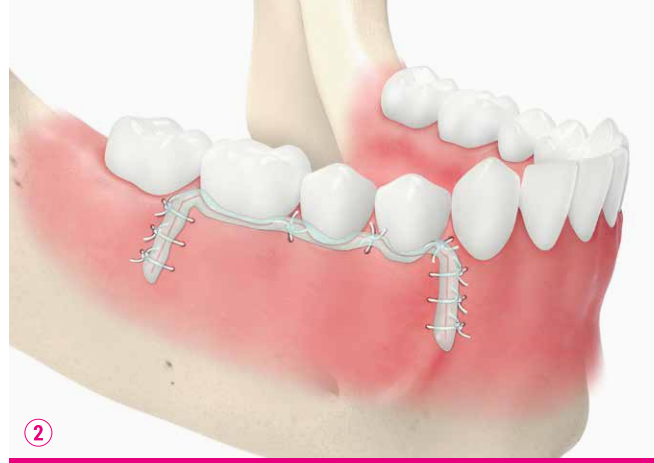

EFFECTS AND MODE OF ACTION

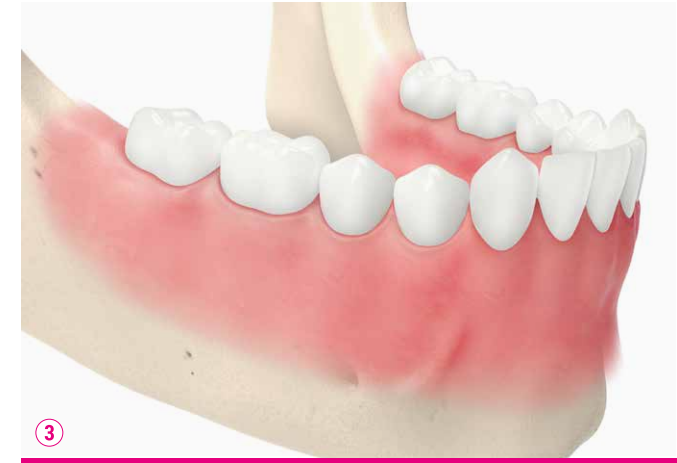INFLAMMATION, PAIN AND SCAR MANAGEMENT



Sutured inflamed site



Gel on suture



Healed site

EMPOWERING REGENERATION

SCIENTIFIC EVIDENCE

Patient discomfort and wound healing of palatal donor sites after free gingival graft (FGG) surgery.¹⁸

Day	VAS Pain Score		VAS Burning Score		VAS Colour Match Score		Complete Epithelisation	
	Control	xHyA	Control	xHyA	Control	xHyA	Control	xHyA
3	6.42*	1.67*	3.50*	0.67*	0	1.17	0	0
7	4.50	1.25*	3.33*	0.92	0.17*	3.08*	0	0
14	1.25	0	1.33*	0	3.75	5.05*	8.3%*	50%*
21	0	0	0	0	5.83	8.33*	66.7%*	100%*

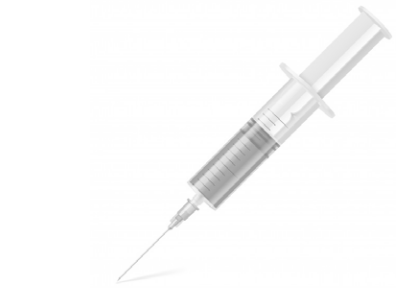Note: VAS score of 0 (no pain/burning sensation) to 10 (severe pain/burning sensation). VAS scores from 0 (no CM) to 10 (excellent CM).

READ THE SCIENTIFIC EVIDENCE

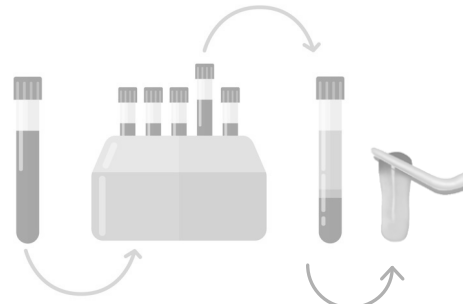


ILLUSTRATION OF RECONSTRUCTION

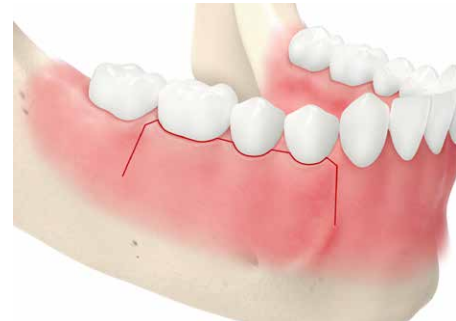USER FRIENDLY, TIME EFFICIENT AND COST EFFECTIVE



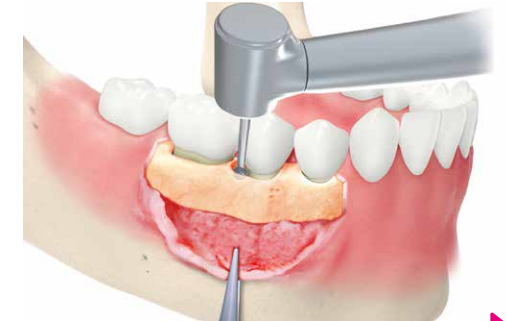No blood taking



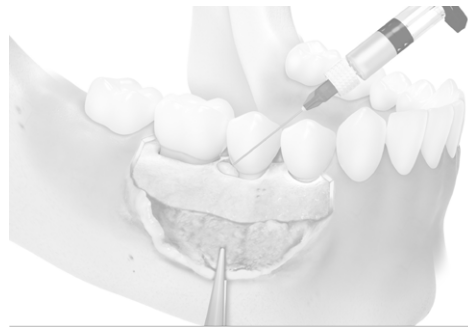
No regenerative material preparation



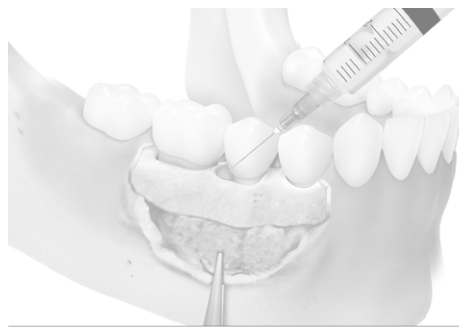1. Open flap



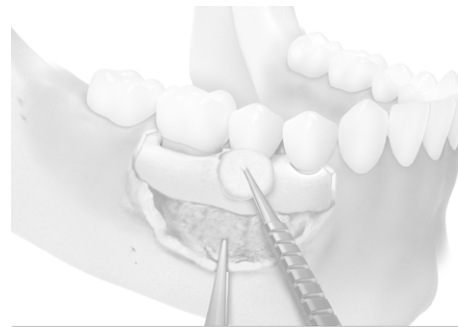
2. Debride



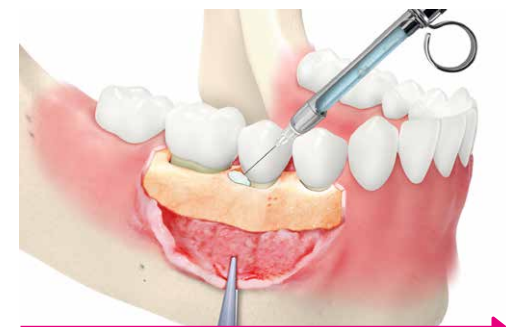No root conditioning



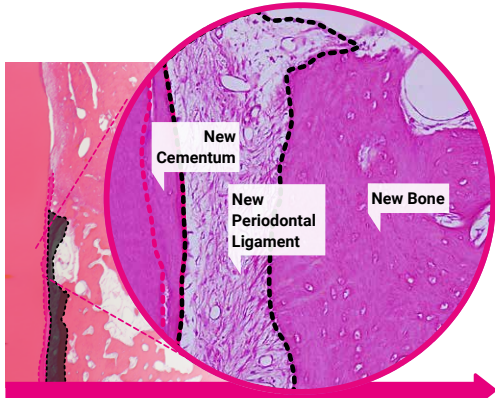
No rinsing



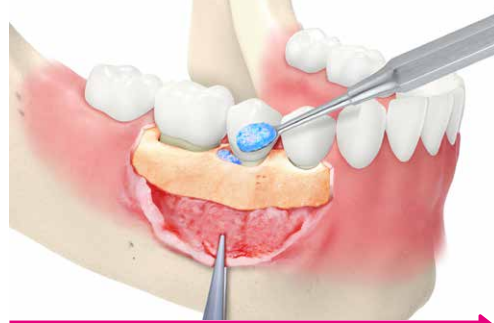No drying, not bloodless



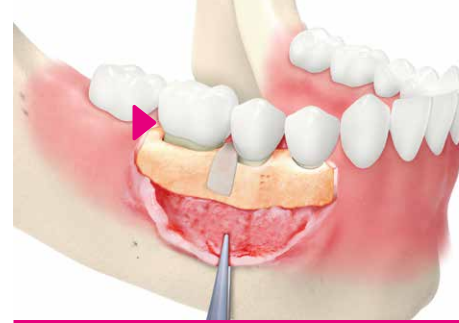3. Inject surgical-grade hyaluronic acid. Observe blood clot stabilisation.



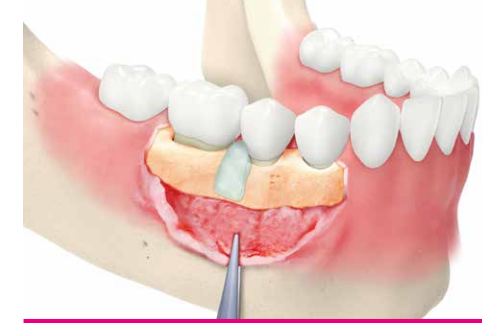4. Regeneration: Periodontal Ligament, Cementum & Bone^{17,22}




5. Sticky Bone: Porcine xenograft & xHyA



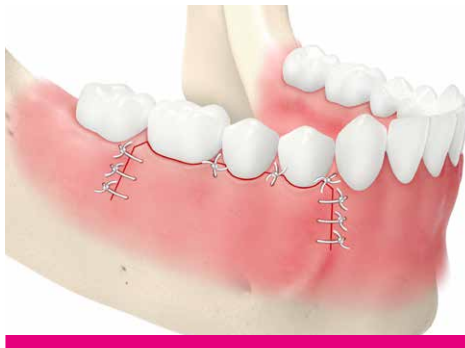6. Apply collagen membrane



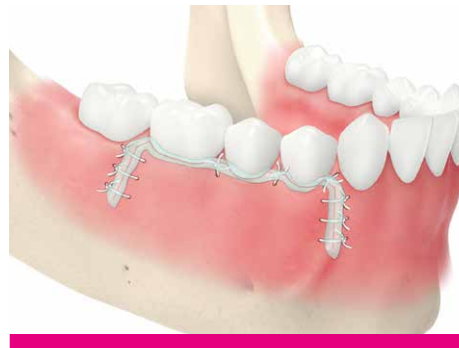7. Apply xHyA on the membrane. Bacteriostatic and anti-inflammatory.



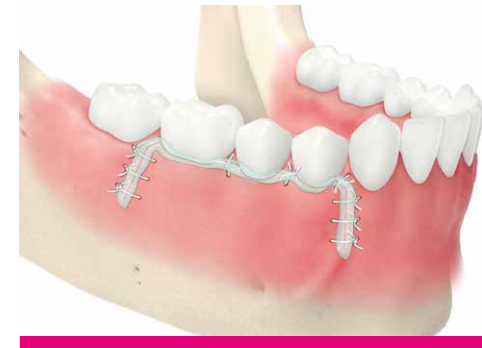8. Collagen membrane resorption slowed down¹⁴



9. Suture



10. Apply the xHyA gel to minimize scar⁶



11. At suture removal: Apply the xHyA gel to minimize scar⁶

CLINICAL WORKFLOW

STICKY BONE IN 3 MINUTES



- Place bone substitute granules into a dish.
- Hydrate using physiological solution or blood.
- Remove any excess fluid.



Add xHyA gel to the hydrated bone substitution material.



- Mix using a spatula.
- Repeat steps 2 & 3: Add additional gel until the desired consistency is reached (ca. 2/3 Vol% graft material, 1/3 Vol% xHyA gel).



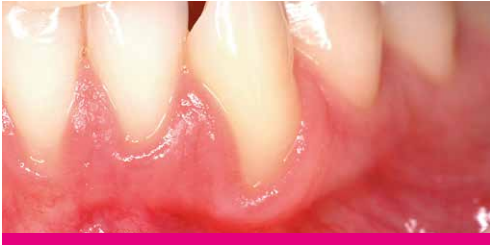Keeping the putty at room temperature for 3-5 minutes may improve the consistency of the putty and make it slightly harder.



Apply putty on to the defect.

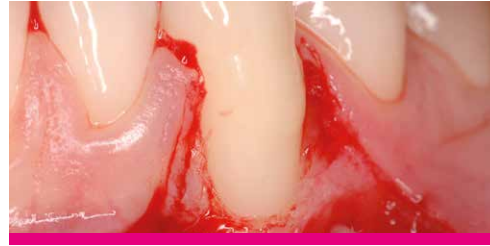GINGIVAL RECESSION (CAF)

CASE PROVIDED BY PROF ANDREA PILLONI, ROME, ITALY



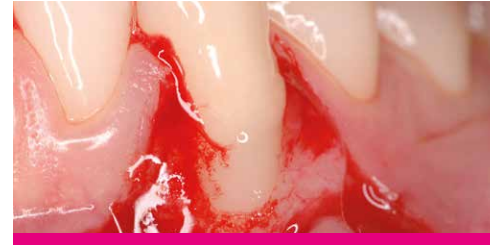1. Pre-operative

A recession defect of Miller Class II was observed in the lower right canine despite the patient's good dental hygiene and regular dental treatment.



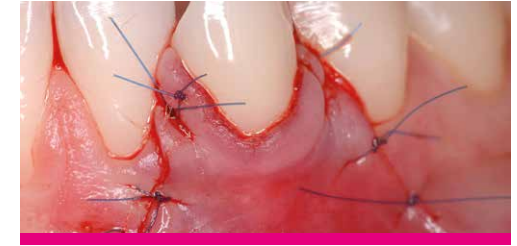
2. Debridement

The recession was treated surgically. After flap preparation, the root surface was carefully cleaned.



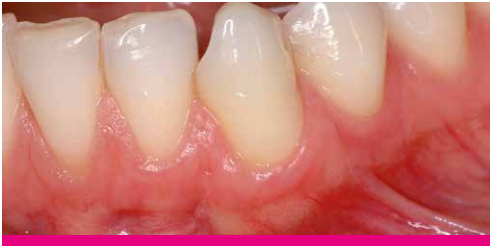3. Injection of the xHyA gel

Surgical-grade xHyA gel was applied on to the root surface and incision areas of the soft tissue to support periodontal regeneration and fast wound healing. The xHyA gel mixes well with blood, which is essential for the clinical efficacy of hyaluronic acid.



4. Suturing

The wound was closed with a Coronally Advanced Flap (CAF).

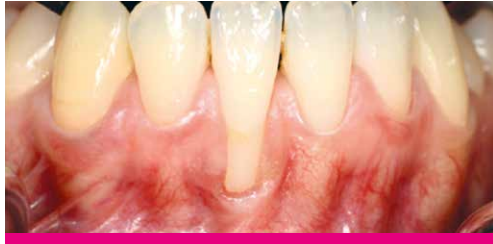

5. 1 year post-operative

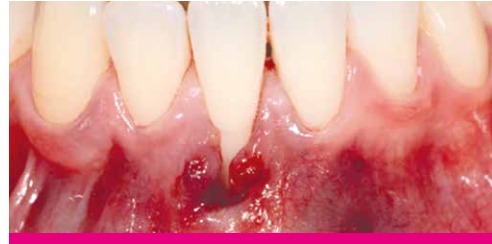The recession remains well covered with healthy soft tissue.

GINGIVAL RECESSION (TUNNEL)

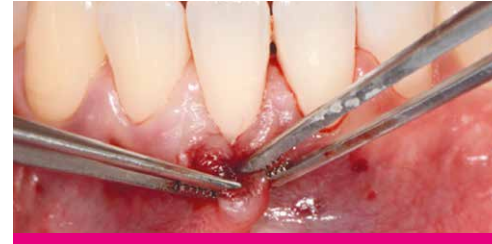CASE PROVIDED BY PROF ANTON SCULEAN, BERN, SWITZERLAND



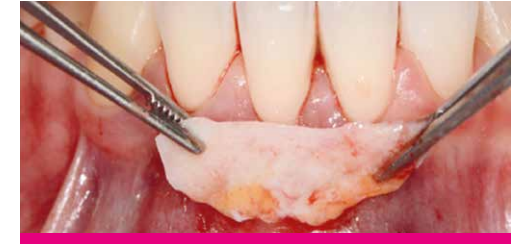1. Baseline



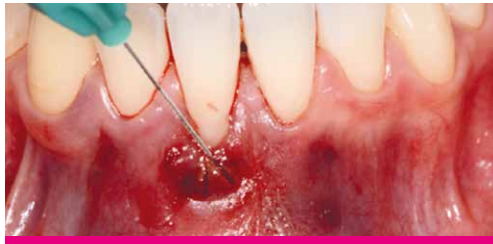2. Tunnel



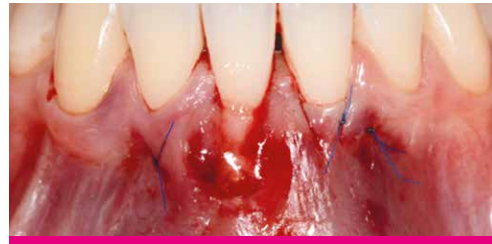3. Mobilized Tunnel



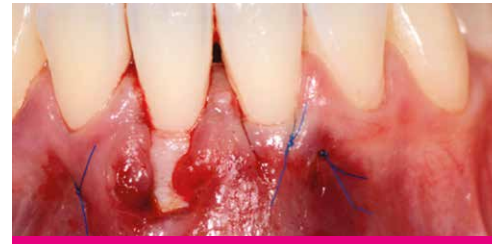4. Connective tissue graft (CTG)



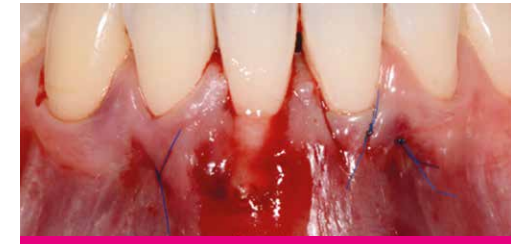5. Application of xHyA gel



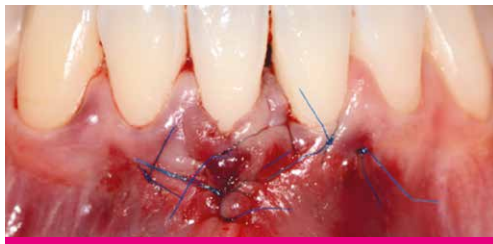6. Applied xHyA gel in the tunnel



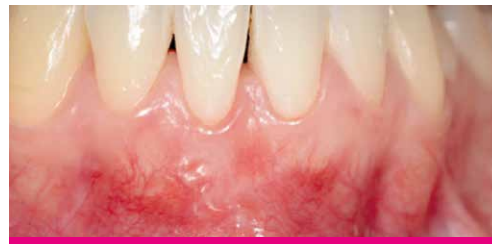7. Connective tissue graft fixed in the tunnel



8. Application of xHyA gel on the connective tissue graft



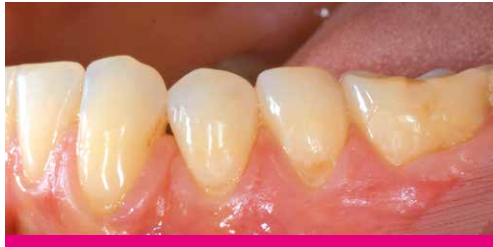9. xHyA gel on laterally closed tunnel (stutured)



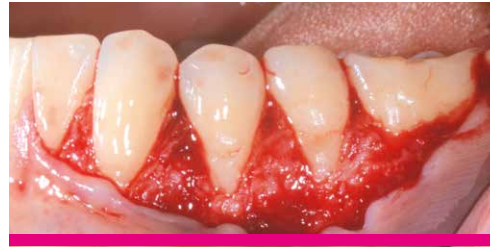10. Outcome

MULTIPLE RECESSION COVERAGE

CASE PROVIDED BY DR JÜRGEN PIERCHALLA, GERMANY



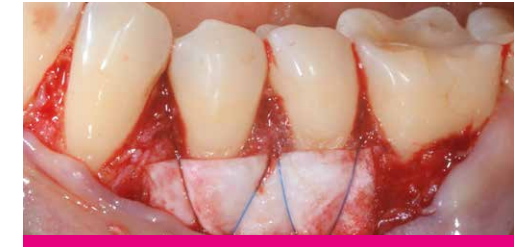1. Pre-operative
Baseline



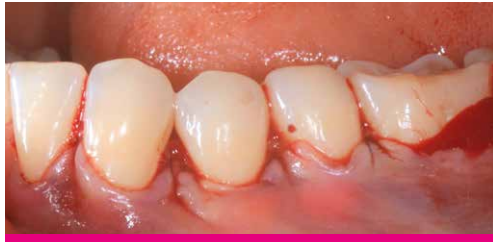2. Surgery
Open flap (CAF protocol)



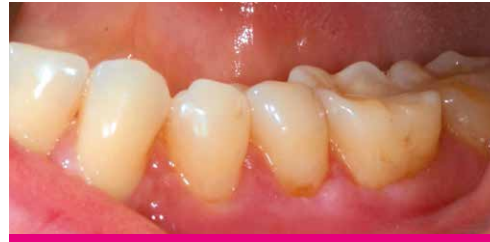3. Smartbrane coated with xHyA gel and folded



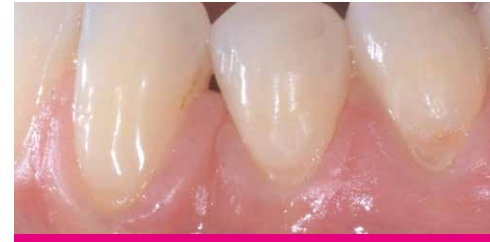4. Suturing on tooth surface of the folded Smart-
brane coated with xHyA gel



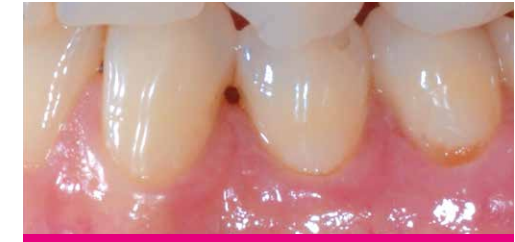5. Suturing the flap



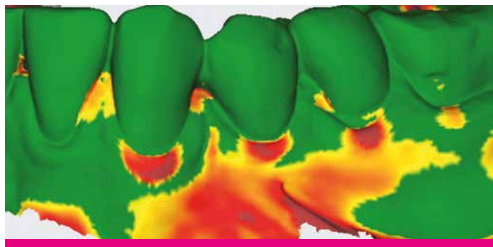
6. Post-operative



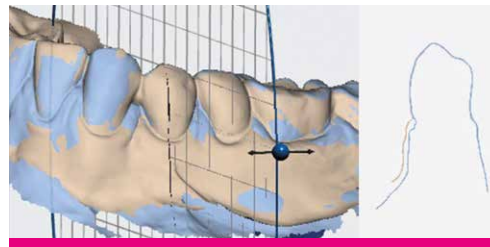
7. Post-operative



8. 9 month post-operative



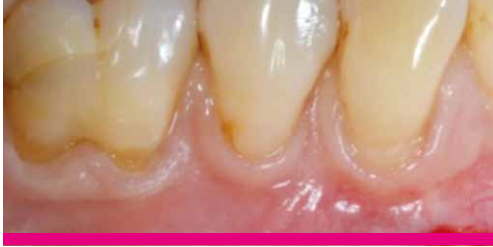9. Soft-tissue volume gain at 9 months post-op vs
baseline



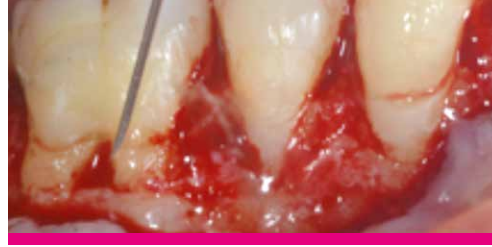10. Cross-section at 9 months post-op vs baseline

FURCATION

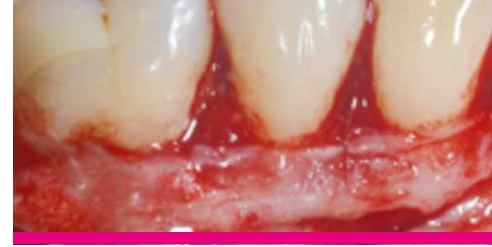CASE PROVIDED BY DR SOFIA AROCA, PARIS, FRANCE



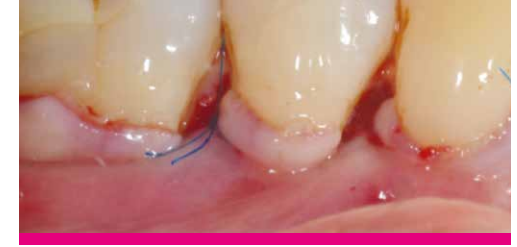1. Diagnosis
Multiple recession (RT1) and class I furcation



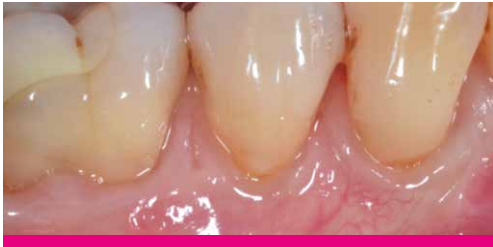2. Application of the xHyA gel
Split-Full-Split flap design and application of surgical-grade xHyA gel. This gel mixes well with blood and stabilizes the blood clot on site.



3. Surgery
The connective tissue graft is sutured and stabilized.



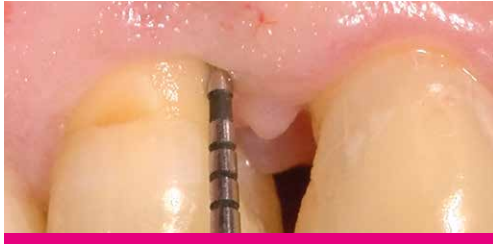4. Suturing
The wound is closed by coronally advancing the flap margin (without tension) by at least 1,5 mm to the cementoenamel junction (CEJ) with separated suspended sutures.



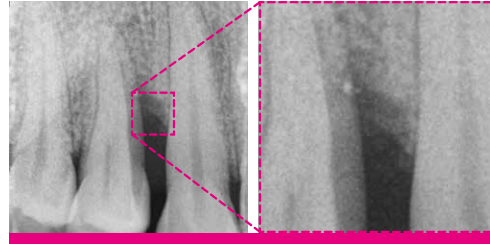
5. Outcome
1 year after the operation: The recession remains well covered with healthy soft tissue and an aesthetic result with minimal scars.

INFRABONY DEFECT

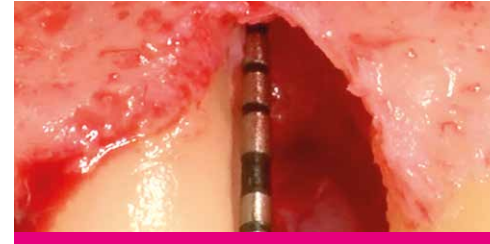CASE PROVIDED BY PROF ANDREA PILLONI, ROME, ITALY



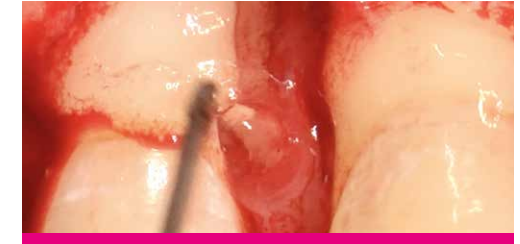1. Initial Situation: PPD of 10 mm



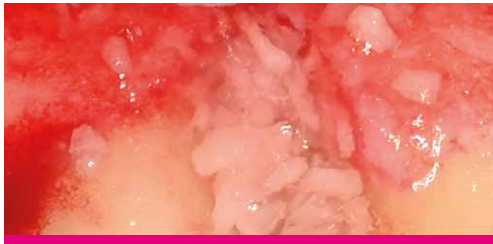2. Initial Situation: PPD of 10 mm



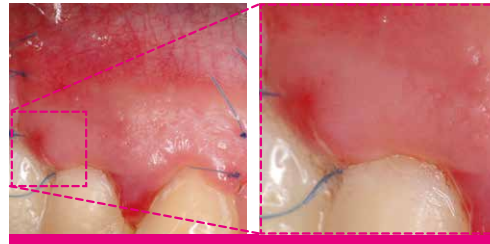
3. Situation after flap preparation and thorough degranulation of defect



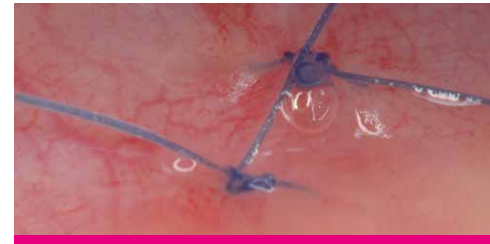4. Defect filled with a mixture of xHyA and a bone filler



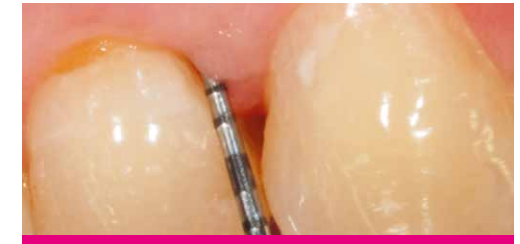5. Defect filled with a mixture of xHyA and a bone filler.



6. Situation 72h post-OP shows accelerated healing.



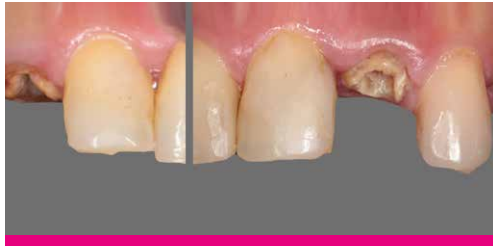7. Situation 72h post-OP shows accelerated healing.



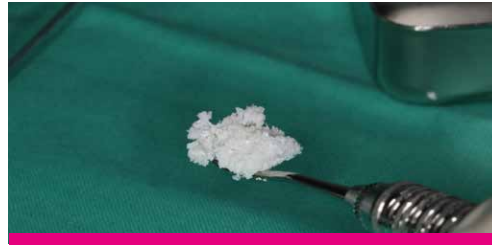8. After 8 years
Significant reduction of probing depth to 2-3 mm

SOCKET PRESERVATION

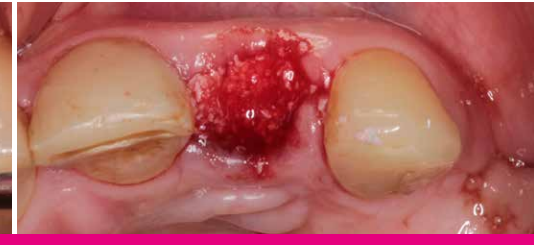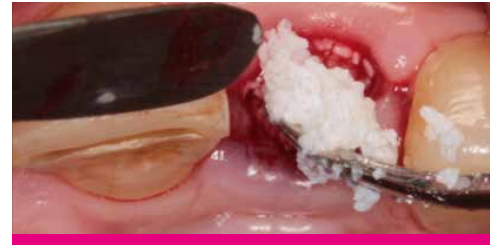CASE PROVIDED BY DR BACHAR HUSSEINI, BEIRUT, LEBANON



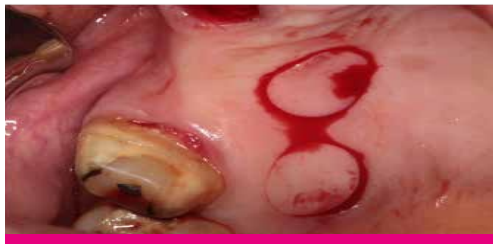1. Split case with socket preservation



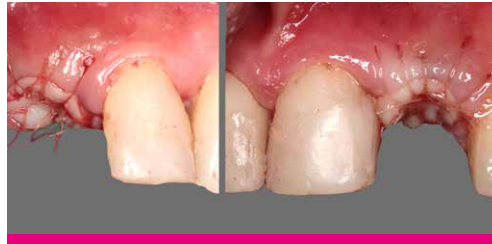2. Sticky bone of DBBM + xHyA gel (right)



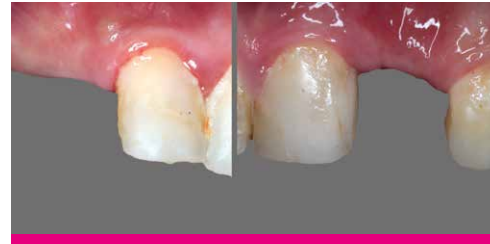3. Filling of sockets with DBBM (left) and sticky bone (right)



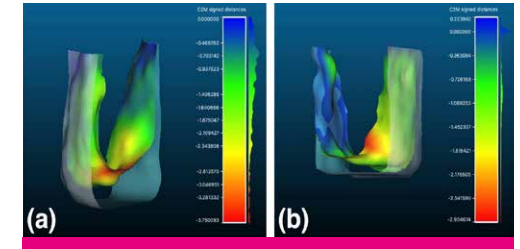
4. Tissue punches



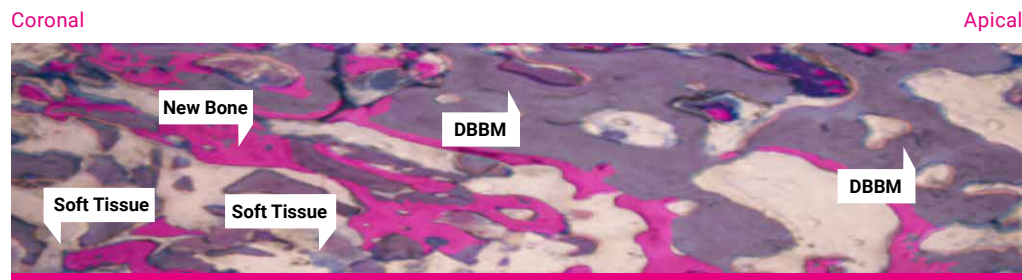
5. Closure of sockets with autogenous tissue



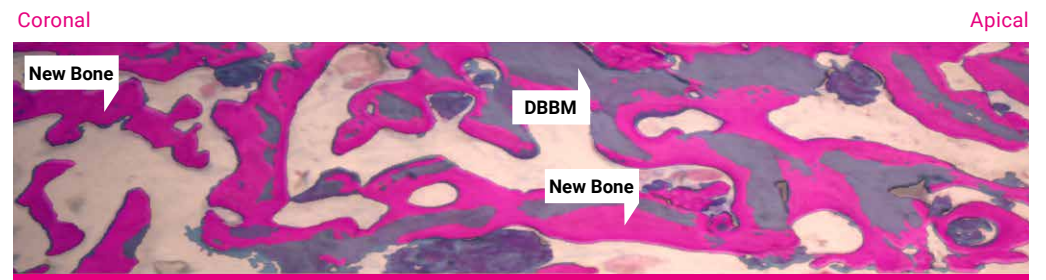
6. Healing at 2 months



7. Volume resorption at 2 months. Limited volume resorption in xHyA+DBBM group (right)



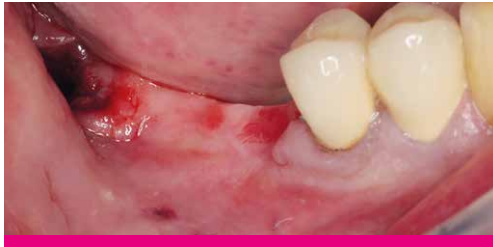Histology DBBM at 2 months. Low amount of new bone cells (pink). Limited resorption of DBBM (grey). Presence of soft tissue (blue).



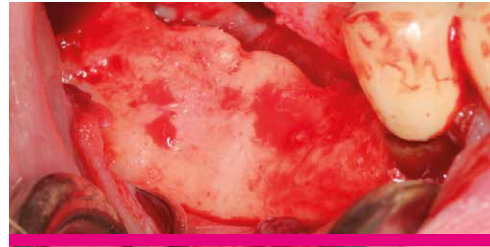
Histology DBBM + xHyA at 2 months. Significant new bone cells. DBBM resorption. Low presence of soft tissues.

GUIDED BONE REGENERATION

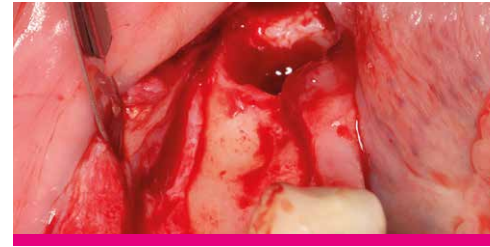
CASE PROVIDED BY PROF DARKO BOŽIĆ, ZAGREB, CROATIA



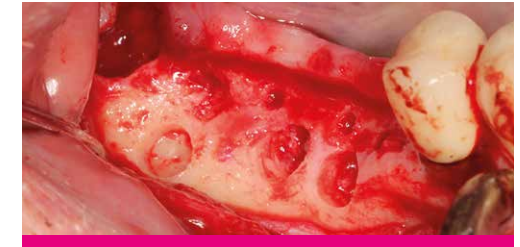1. Patient with a distal mandibular edentulous ridge requiring implant placement



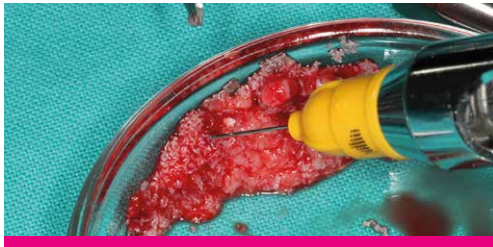2. Flap elevation revealed significant loss of ridge height and width.



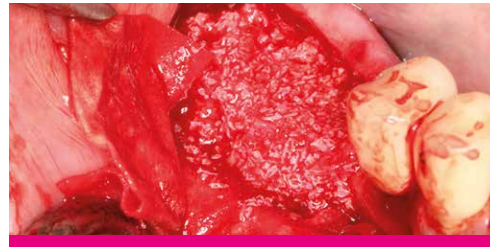3. Edentulous ridge with significant loss of height and width



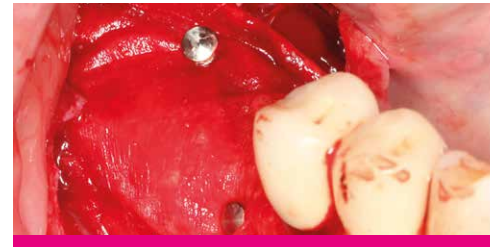4. A small amount of autogenous bone was harvested leaving small cortical perforations.



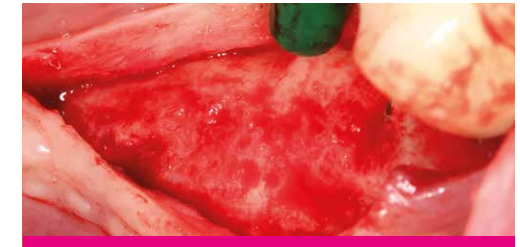5. The autogenous bone was mixed with xenograft material saturated with xHyA.



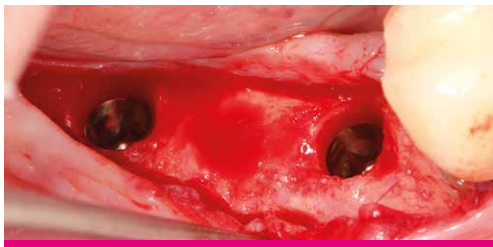6. Placement and adaptation of the graft mixture onto the recipient site



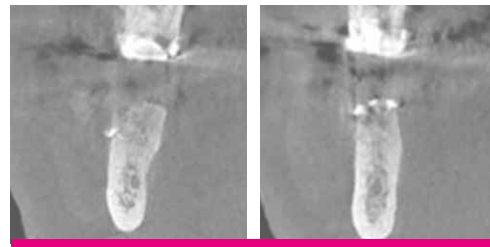
7. The graft mixture was covered with a resorbable collagen membrane (SMARTBRANE) and fixed with pins.



8. After 6 months
Significant gain of bone width with almost no residual graft particles visible



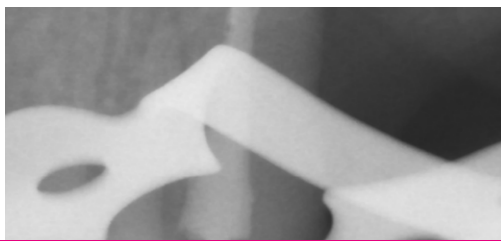
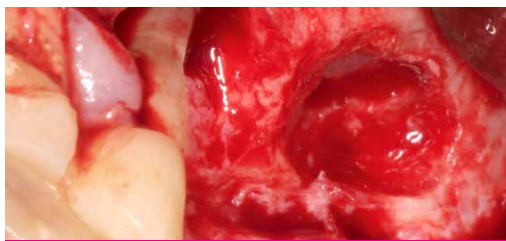
9. Implants of 4mm width were placed in the correct prosthetic positions.



10. After 6 months
Cone beam computed tomography (CBCT) showing a significant amount of newly formed bone.

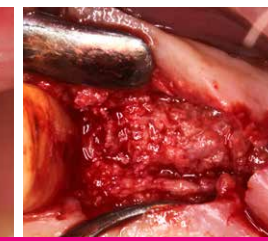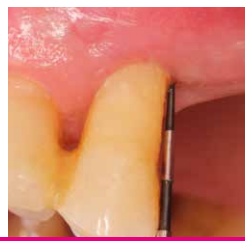
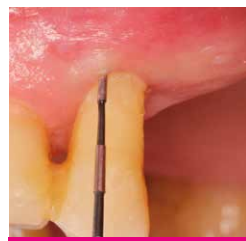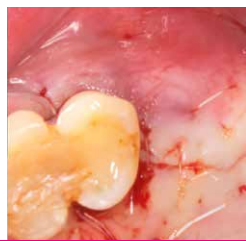
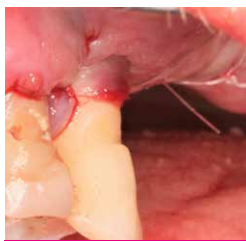PERIODONTAL TREATMENT AND SINUS ELEVATION

CASE PROVIDED BY PROF. A. FRIEDMANN, WITTEN/HERDECKE, GERMANY



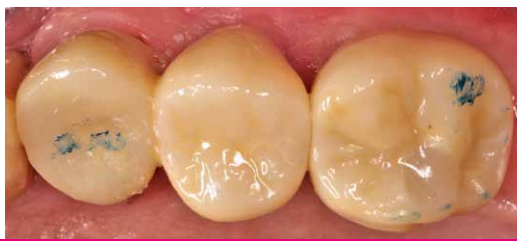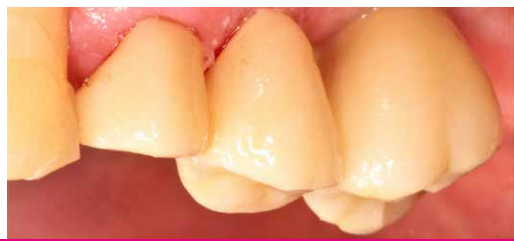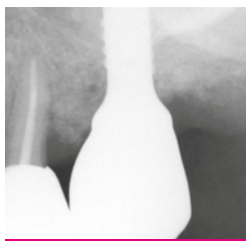
1. Hopeless premolar with periodontal treatment and sinus elevation

2. Sticky bone with cross-linked hyaluronic acid (xHyA) gel combined with porous porcine xenograft granules

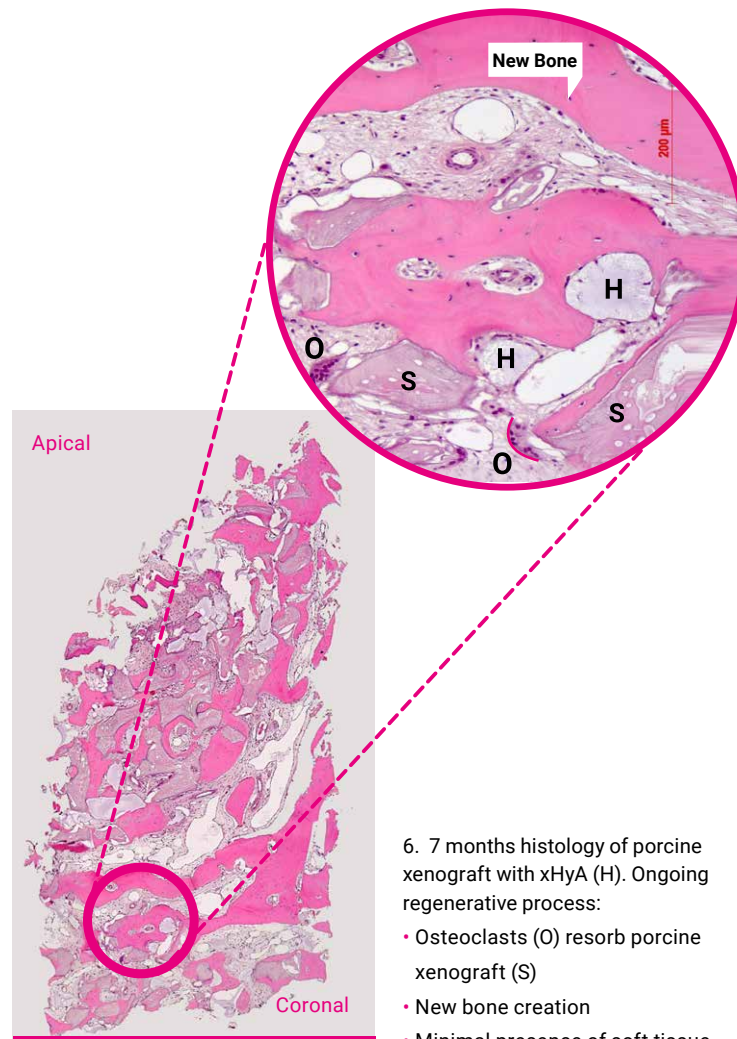


3. Post-op situation

4. 7m post-OP: PD \leq 3 mm / BoP negative / CAL gain at 7 months \approx 5.5 mm. Re-entry discloses defect resolution at distal wall



5. Final prosthetic work



6. 7 months histology of porcine xenograft with xHyA (H). Ongoing regenerative process:

- Osteoclasts (O) resorb porcine xenograft (S)
- New bone creation
- Minimal presence of soft tissue

LITERATURE

1. Lee JY, Spicer AP. 'Hyaluronan: a multifunctional, megadalton, stealth molecule.' *Curr Opin Cell Biol* 2000;12:581–586.
2. McDonald J, Hascall VC. 'Hyaluronan mini review series.' *JBiol Chem* 2002; 277:4575–4579.
3. Jiang D et al. 'Hyaluronan as an immune regulator in human diseases.' *Physiol Rev* 2011;91:221–264.
4. Longaker T et al. 'Studies in Fetal Wound Healing: V. A prolonged presence of hyaluronic acid characterizes fetal wound healing.' *Ann. Surg.* 1991; April:292–296.
5. Mast BA et al. 'Hyaluronic Acid Modulates Proliferation, Collagen and Protein Synthesis of Cultured Fetal Fibroblast.' *Matrix*, 1993;13:441–446.
6. Asparuhova MB et al.. 'Activity of two hyaluronan preparations on primary human oral fibroblasts.' *J Periodont Res.* 2018;00:1–13.
7. Salbach J et al. 'Regenerative potential of glycosaminoglycans for skin and bone.' *J Mol Med* 2012;90:625–635.
8. Muzaffer A et al. 'The Effect of Hyaluronic Acid-supplemented Bone Graft in Bone Healing: Experimental Study in Rabbits.' *J Biomater Appl* 2006 20:209
9. Sasaki T, Watanabe C. 'Stimulation of osteoinduction in bone wound healing by high-molecular hyaluronic acid.' *Bone.* Vol. 16. No.1 January 1995:9-15
10. Pirnazar P et al. 'Bacteriostatic effects of hyaluronic acid.' *Journal of Periodontology* 1999; 70:370-374
11. De Boule K et al. 'A Review of the Metabolism of 1,4-Butanediol Diglycidyl Ether– Crosslinked Hyaluronic Acid Dermal Fillers.' *Dermatologic Surgery* 2013;39(12):1758-1766
12. Stiller M et al. 'Performance of β -tricalcium phosphate granules and putty, bone grafting materials after bilateral sinus floor augmentation in humans.' *Biomaterials* 2014;35(10):3154-3163.
13. Mendes RM et al. 'Sodium hyaluronate accelerates the healing process in tooth sockets of rat.' *Arch Oral Biol* 2008; 53:1155–1162
14. Eliezer M et al. 'Hyaluronic acid slows down collagen membrane degradation in uncontrolled diabetic rats.' *J Periodontal Res.* 2019;00:1–9.
15. Kessiena LA et al. 'Hyaluronan in wound healing: Rediscovering a major player.' *Wound Rep Reg* 2014;22:579-593. *Dental Journal.* (2017) Vol.42:104-11.
16. West DC et al. 'Angiogenesis induced by degradation products of hyaluronic acid.' *Science.* 1985 Jun 14;228(4705):1324-6.
17. Shirakata Y, Imafuji T, Nakamura T, Kawakami Y, Shinohara Y, Noguchi K, Pilloni A, Sculean A. Periodontal wound healing regeneration of two-wall intrabony defects following reconstructive surgery with cross-linked hyaluronic acid-gel with or without a collagen matrix: a preclinical study in dogs. *Quintessence Int.* 2021;0(0):308-316. doi: 10.3290/j.qi.b937003. PMID: 33533237.
18. Yıldırım S, Özener HÖ, Doğan B, Kuru B. Effect of topically applied hyaluronic acid on pain and palatal epithelial wound healing: An examiner-masked, randomized, controlled clinical trial. *J Periodontol.* 2018 Jan;89(1):36-45. doi: 10.1902/jop.2017.170105. PMID: 28914592.
19. King, S.R., Hickerson, W.L. and Proctor, K.G. (1991) Beneficial Actions of Exogenous Hyaluronic Acid on Wound Healing. *Surgery*, 109, 76-86.
20. Fawzy ES. et al. Local application of hyaluronan gel in conjunction with periodontal surgery: a randomized controlled trial. *Clin Oral Invest* 2012;16:1229-1236
21. Briguglio, F. et al. Treatment of infrabony periodontal defects using a resorbable biopolymer of hyaluronic acid: A randomized clinical trial. *Quintessence Int* 2013;44:231-240
22. Shirakata Y, Nakamura T, Kawakami Y, Imafuji T, Shinohara Y, Noguchi K, Sculean A. Healing of buccal gingival recessions following treatment with coronally advanced flap alone or combined with a cross-linked hyaluronic acid gel. An experimental study in dogs. *J Clin Periodontol.* 2021. doi: 10.1111/jcpe.13433.
23. Pilloni A, Schmidlin PR, Sahrman P, Sculean A, Rojas MA. 'Effectiveness of adjunctive hyaluronic acid application in coronally advanced flap in Miller class I single gingival recession sites: a randomized controlled clinical trial, *Clinical Oral Investigations*
24. Fickl et al. 2021 (submitted)
25. Bachar Hussein et al 2021 (submitted)

Note: Smartgraft is a registered brand of Regedent AG and manufactured by Collagen Matrix Inc. HYADENT BG is a registered brand and manufactured by BioScience GmbH. Smartbrane is a registered brand and manufactured by Regedent AG

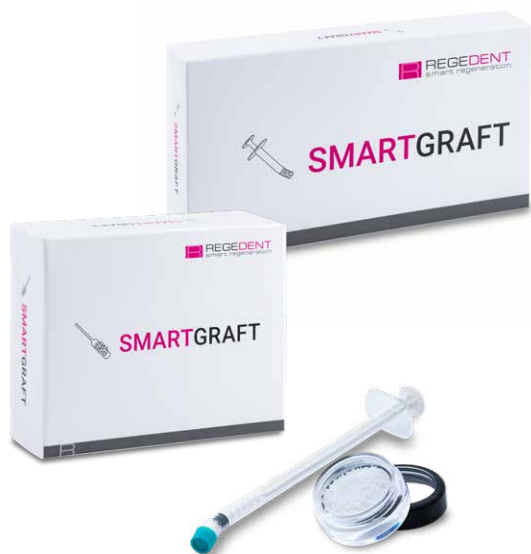READ THE SCIENTIFIC EVIDENCE



OPTIONS

	Xenograft	Collagen membrane	xHyA
Root coverage with CTG			1 x 1.2 ml
Intraosseous defect (1-3 walls)/furcations (class I-III)	0.25 – 1.0 mm granules	15 x 20 mm	1 x 1.2 ml
Fenestration defect	0.5 cc or 1 cc of fine particles	20 x 30 mm	1 x 1.2 ml
Implant dehiscence	0.5 cc or 1 cc of fine particles	15 x 20 mm	1 x 1.2 ml
Extraction socket	1.0 cc of fine particles	10 x 10 mm or 15 x 20 mm	1 x 1.2 ml
Vertical / horizontal augmentation	2.0 cc of large particles	20 x 30 mm ou 30 x 40 mm	1 x 1.2 ml
Ridge preservation	2.0 cc of large particles	30 x 40 mm	1 x 1.2 ml
Sinus floor elevation	2.0 cc of large particles	15 x 20 mm or 20 x 30 mm	1 x 1.2 ml
Protection Schneiderian membrane		15 x 20 mm or 20 x 30 mm	1 x 1.2 ml
Scar healing / esthetics			1 x 1.2 ml

AVAILABLE PRODUCTS



hyadENT BG

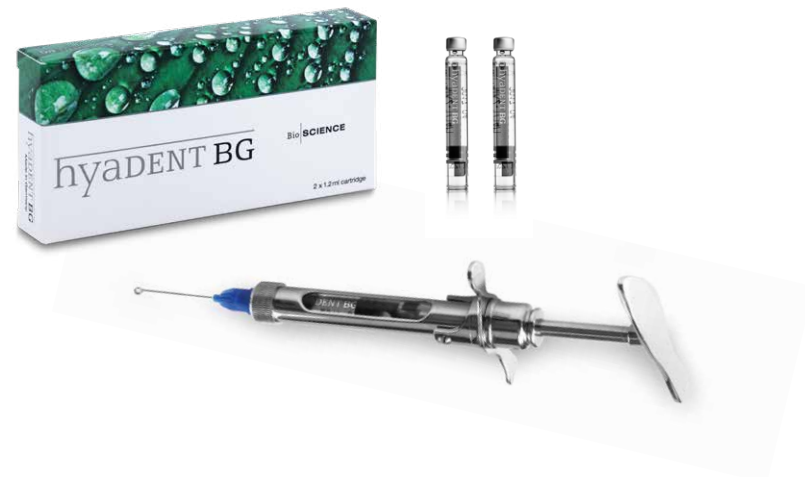Size	Article number
2 x 1.2 ml ampulla	BS091

SMARTGRAFT

Size	Article number
0.50 cc / 0.25 – 1.00 mm	0114.101
1.00 cc / 0.25 – 1.00 mm	0114.102
2.00 cc / 0.25 – 1.00 mm	0114.103
4.00 cc / 0.25 – 1.00 mm	0114.105
1.00 cc / 1.00 – 2.00 mm	0114.112
2.00 cc / 1.00 – 2.00 mm	0114.113
0.25 cc / 0.25 – 1.00 mm syringe	0114.450
0.50 cc / 0.25 – 1.00 mm syringe	0114.451

SMARTBRANE

Size	Article number
10 x 10 mm	0121.200
15 x 20 mm	0121.201
20 x 30 mm	0121.202
30 x 40 mm	0121.203



PARADENT